

Pathogenicity of *Mycobacterium fortuitum* and
Mycobacterium smegmatis to goldfish,
Carassius auratus

Adel M. Talaat^{a,b,1}, Michele Trucksis^{a,c}, Andrew S. Kane^b,
Renate Reimschuessel^{b,*}

^aCenter for Vaccine Development, Division of Geographic Medicine, Department of Medicine,
University of Maryland School of Medicine, Baltimore, MD 21201, USA

^bDepartment of Pathology, University of Maryland School of Medicine, Baltimore, MD 21201, USA

^cMedical Service, Veterans' Affairs Medical Center, Baltimore, MD 21201, USA

Received 3 June 1998; accepted 22 December 1998

Abstract

Despite the ubiquitous presence of atypical mycobacteria in the environment and the potential risk of infection in humans and animals, the pathogenesis of diseases caused by infection with atypical mycobacteria has been poorly characterized. In this study, goldfish, *Carassius auratus* were infected either with the rapidly growing fish pathogen, *Mycobacterium fortuitum* or with another rapidly growing mycobacteria, *Mycobacterium smegmatis*. Bacterial persistence and pathological host response to mycobacterial infection in the goldfish are described. Mycobacteria were recovered from a high percentage of inoculated fish that developed a characteristic chronic granulomatous response similar to that associated with natural mycobacterial infection. Both *M. fortuitum* and *M. smegmatis* were pathogenic to fish. Fish infected with *M. smegmatis* ATCC 19420 showed the highest level of giant cell recruitment compared to fish inoculated with *M. smegmatis* mc²155 and *M. fortuitum*. Of the three strains of mycobacteria examined, *M. smegmatis* ATCC 19420 was the most virulent strain to goldfish followed by *M. fortuitum* and *M. smegmatis* mc²155, respectively. © 1999 Elsevier Science B.V. All rights reserved.

Keywords: Fish; Virulence; Mycobacteria; *Mycobacterium fortuitum*; *Mycobacterium smegmatis*; Pathogenesis

* Corresponding author. Present address. Food and Drug Administration, Center for Veterinary Medicine, Office of Research, 4801 Muirkirk Road, Laurel, MD 20708, USA. Tel.: +1-301-827-8025; e-mail: rreimsch@bangate.fda.gov

¹ Present address: University of Texas Southwestern medical center, Department of internal medicine, 5323 Harry Hines Blvd., Dallas, TX 75235, USA.

1. Introduction

Mycobacterium fortuitum and *Mycobacterium smegmatis* have been placed in one class of rapidly growing atypical mycobacteria (Runyon, 1959). These species of mycobacteria are isolated from multiple sources in the environment including soil and water (Goslee and Wolinsky, 1976; Kamala et al., 1994). *M. fortuitum* has been considered a pathogen for both animals and humans since its first isolation from a human abscess in 1938 (Cruz, 1938). *M. fortuitum*, as well as *Mycobacterium marinum* and *Mycobacterium chelonae*, are the mycobacterial species commonly associated with fish tuberculosis (Belas et al., 1995). Fish tuberculosis is a systemic, chronic disease characterized by the presence of granulomatous reaction in visceral organs accompanied by continuing mortalities in the infected stock (Hedrick et al., 1987; Daoust et al., 1989; Wallace et al., 1994). *M. fortuitum* has also been implicated in cases of cattle and sheep mastitis (Richardson, 1971), canine pulmonary and subcutaneous abscesses (Jang et al., 1984; Fox et al., 1995), feline cutaneous granulomas (Wilkinson et al., 1978) as well as the mouse neurological disorder, 'spinning disease' (Saito and Tasaka, 1969).

Nosocomial infections with *M. fortuitum* have been traced to contaminated water sources in hospitals (Brown, 1985). Most *M. fortuitum* infections are either wound infections resulting in abscesses or postoperative infections such as sternotomy wound infections and prosthetic valve endocarditis (Woods and Washington II, 1987; Yew et al., 1993).

In humans, *M. smegmatis* was first isolated from syphilitic chancres (Bloom, 1885) and normal genital secretions (Alvarez, 1885). After its initial isolation from the genitourinary tract, these bacilli have been recognized as environmental saprophytes (Kamala et al., 1994). In an animal model, an oil suspension of *M. smegmatis* produced a clinical mastitis in sheep after intramammary infusion (Richardson, 1971). Similarly, *M. smegmatis*-induced granulomatous mastitis was seen in a dairy herd after intramammary treatment (Thomson et al., 1988). Recently, the organism has been implicated in systemic granulomatous lesions in an immunocompromised dog (Grooters et al., 1995). *M. smegmatis* has been implicated in clinical cases of sternal wound infection, breast abscesses, endocarditis, lymphadenitis, osteomyelitis, cellulitis as well as lipoid and aspiration pneumonia (Wallace Jr. et al., 1988; Newton Jr. et al., 1993; Newton Jr. and Weiss, 1994). Even though *M. smegmatis* is pathogenic to animals and humans under some circumstances, this organism is generally considered to be a non-pathogenic species for the frog- and the tissue culture- models of infections (Shepard, 1957; Falcone et al., 1994; Barker et al., 1996; Ramakrishnan et al., 1997).

Although *M. fortuitum* is pathogenic to animals and humans, neither the molecular pathogenesis of this organism nor the virulence determinants have been identified. Previously, we developed goldfish and *M. marinum* as a model system for studying pathogenesis of the slowly growing mycobacteria (Talaat et al., 1998). In this study, we compared the virulence of the rapidly growing mycobacteria, *M. fortuitum* and *M. smegmatis* using goldfish, *Carassius auratus*. We were able to reproduce the characteristic features of mycobacterial infection after inoculating goldfish with either *M. smegmatis* or *M. fortuitum*.

2. Materials and methods

2.1. Animal

Goldfish (4–5 inches, 20–30 g) were obtained from a local commercial fish farm (Hunting Creek Fisheries, Hunting Creek, MD). The fish were quarantined (with a photoperiod of 16 h light and 8 h dark) in flow-through tanks (50 l), for at least 2 weeks prior to use in the study. Fish were treated twice with addition of 100 ppm (part per million) of formalin 37% to the tank for 1 h, as a prophylactic program against parasitic infestation. During quarantine, fish were examined for parasitic or bacterial infection by skin scrapes, gill biopsy, fecal examination and bacteriological culturing prior to inoculation. The fish were fed a pelleted fish chow (36% protein) purchased from a commercial supplier (Ziegler Bros., Gardner, PA).

2.2. Bacteria

M. fortuitum ATCC 6841 and *M. smegmatis* ATCC 19420 were purchased from American Type Culture Collection (ATCC, Rockville, MD). *M. smegmatis* mc²155 was a gift from Dr. R. Belas (University of Maryland Biotechnology Institute). *M. smegmatis* mc²155 is non-pathogenic (Barker et al., 1996; Ramakrishnan et al., 1997) and transformation-efficient strain of mycobacteria derived from *M. smegmatis* mc²6 (Snapper et al., 1990). *M. smegmatis* mc²155 is commonly used as a cloning host for the study of genes from virulent mycobacteria (Parish and Stoker, 1995). *M. fortuitum* was grown in Dubos broth (Difco, Detroit, MI) at 37°C while *M. smegmatis* (ATCC 19420 and mc²155) was cultured in 7H9 broth supplemented with albumin-dextrose complex (ADC) (Difco) at 37°C (Jacobs Jr. et al., 1991). Inocula for animals were obtained from the mid-exponential growth phase cultures and concentrated or diluted to the specified colony forming units per milliliter (cfu/ml). The number of cfu/ml was determined by plating on 7H10 agar (Difco) at 37°C. Clumps of bacteria were dissociated by sonication for 3 min (power level 3) while cooling in a cup horn accessory attached to a cell disrupter (model W-220 F, Heat Systems; Ultrasonics, Farmingdale, NY).

2.3. Experimental design

After the quarantine period, fish were transferred from the quarantine room to the experimental room, and randomly housed in separate tanks (6–10 fish/50 l tank). Groups of goldfish (total of 166 fish, 6–10 fish per group) were intraperitoneally inoculated through the lateral abdominal musculature with 0.5 ml of varying concentrations of either *M. fortuitum*, *M. smegmatis* or phosphate buffered saline (PBS, control fish group) by using a 25-gauge needle and tuberculin syringe (Talaat et al., 1998). A total of 45 fish were inoculated with PBS in four separate experiments. Each group of fish was housed in a separate aquarium. Between four to eight fish were sacrificed at 2, 4, 6 and 8 weeks post-inoculation, or when they became moribund. At sacrifice, 100 mg of liver, spleen and kidney were collected under aseptic conditions for bacteriological examination, to

determine the cfu/gm of collected tissue. Dilutions of the collected organ homogenates (100 mg in 0.5 ml PBS with 0.05% Tween-80) were plated on 7H10 agar and incubated at 37°C. The remaining tissue, including liver, spleen and kidney tissues, were sampled for histological examination. Some animals were found dead and unfit for histological examination. All the experiments were repeated at least twice.

2.4. Tissue and colony PCR

Mycobacteria were identified to the species level from isolated colonies as well as from infected fish tissues using diagnostic PCR (Talaat et al., 1997). Briefly, a 924 bp DNA fragment is amplified from both *M. fortuitum* and *M. smegmatis* by using *Mycobacterium* genus-specific primers designed from a highly conserved region of 16S rRNA. The amplified product was analyzed by restriction enzyme digestion with *BanI* (New England Biolabs, NEB, Beverly, MA). The digestion yields two fragments, 562 and 362 bp, with the amplified *M. fortuitum* fragment, while the *M. smegmatis* product remains intact. Colony and tissue sample processing for PCR is as described previously (Talaat et al., 1997).

2.5. Histopathology

Tissues (spleen, liver, intestine, peritoneum, brain, heart, muscle, skin, gonads and kidney) from each fish were collected and processed in 10% neutral-buffered formalin, washed in running tap water, dehydrated in ethanol and embedded in paraffin wax by standard procedures (Prophet, 1992). 5 µm sections of the paraffin embedded tissues were prepared with a rotary microtome (American Optical, Buffalo, NY) and stained with H and E (Prophet, 1992). Selected sections were stained with modified Ziehl-Neelsen stain (Ellis and Zabrowarny, 1993). The microscopic pathology of H and E stained slides of each tissue was scored independently by two pathologists (A.T. and R.R.) using a scale of 0–5. A score of 0 is normal; 1, minimal; 2, mild; 3, moderate; 4, marked and 5, severe (Reimschuessel et al., 1992). This scoring system was necessary to evaluate the inflammatory response elicited in the peritoneum of fish, referred to as peritoneal score (PS). The mean of PSs of each group of infected fish is referred to as, mean peritoneal score (MPS). When granulomas developed in infected animals, the same scale (from 0–5) was used to estimate the granuloma score (GS) elicited in the peritoneum as well as in the liver, spleen, heart and kidney. Each fish had a cumulative granuloma score (CGS) reflecting the sum of GS of the peritoneum, liver, spleen, heart and kidney. The mean cumulative granuloma score (MCGS) is the mean of CGS of a group of infected fish group.

2.6. Statistical analysis

Mycobacterial colony counts from fish organs and the pathology scores at different time points were analyzed by the analysis of variance (ANOVA) for differences between two or several independent means.

3. Results

3.1. Recovery of *M. fortuitum* and *M. smegmatis* from organs

To determine the persistence of *M. fortuitum* and *M. smegmatis* mc²155 in fish organs, we inoculated goldfish with 10^7 cfu of each mycobacterial species and monitored the mycobacterial colony counts over an 8-week period in the liver, spleen and kidney of infected animals. Mycobacteria were recovered from at least one organ of all animals examined. A representative number of colonies were further identified by diagnostic PCR and/or Ziehl-Neelsen staining.

In the *M. fortuitum* infected group, mycobacterial colony counts remained essentially unchanged during the 8-week period (Fig. 1). In the *M. smegmatis* infected group, however, colony counts significantly declined in the kidney compared to that of the liver ($p < 0.02$) and spleen ($p < 0.01$) after 2 weeks postinoculation (Fig. 2). Mycobacteria were recovered from organs of all the sacrificed fish that were inoculated with 10^8 or 10^9 cfu of either *M. smegmatis* or *M. fortuitum*.

M. fortuitum was isolated from five of 45 PBS inoculated animals probably reflecting the background level of *M. fortuitum* in our goldfish stock. Culture-positive animals were clinically and histopathologically normal.

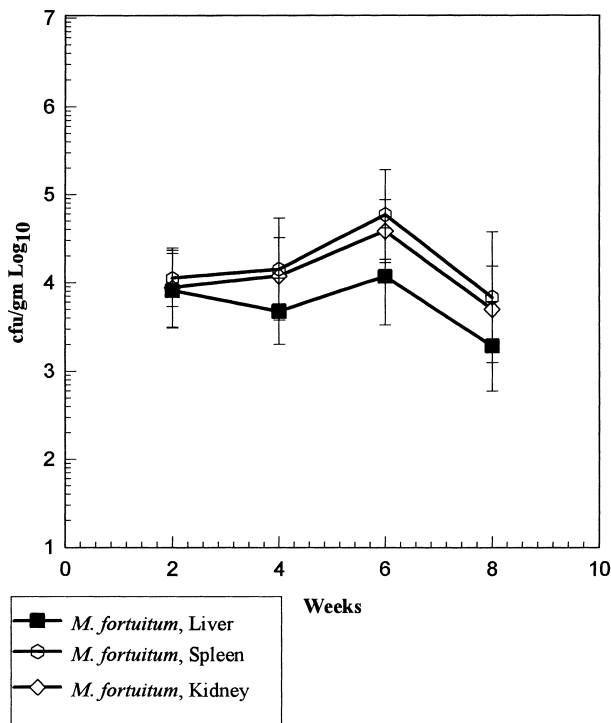


Fig. 1. Recovery of *M. fortuitum* from liver, spleen and kidney of fish inoculated with 10^7 cfu. Results are given as geometric means \pm two standard errors for eight fish per time point.

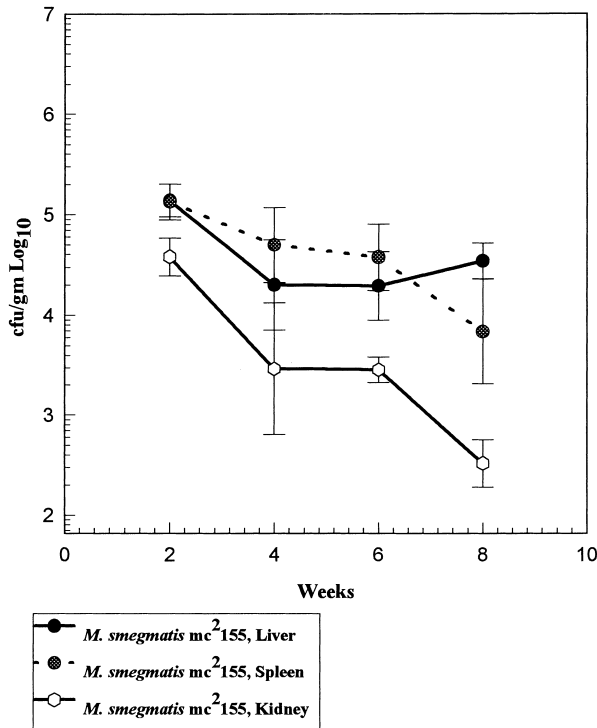


Fig. 2. Recovery of *M. smegmatis* mc²155 from liver, spleen and kidney of fish inoculated with 10^7 cfu. Results are given as geometric means \pm two standard errors for four fish per time point.

3.2. Histopathology of fish infected with *M. fortuitum*

Mycobacteria-inoculated fish showed different pathology according to the species inoculated, the inoculum dose and the post infection survival time. To compare the pathogenicity of the virulent *M. fortuitum* to the other rapidly growing mycobacteria (the avirulent *M. smegmatis*) we inoculated separate groups of goldfish with *M. fortuitum* ATCC 6841 or *M. smegmatis* mc²155 at different doses. At 10^7 cfu of *M. fortuitum*, all animals appeared clinically well during the 8-week observation period. By 8 weeks postinoculation, histological examination of infected fish showed moderate peritonitis and peritoneal granuloma formation in 20% and 33%, respectively, of infected fish. Peritonitis in fish is characterized by accumulation of macrophages, lymphocytes and fibrous connective tissue around the intestine, pancreas, spleen and liver. Granulomas are characterized by the presence of a central caseous or necrotic-caseous area, lymphocytes, macrophages and epithelioid cells surrounded with fibrous connective tissue. The overall MCGS in *M. fortuitum*-infected fish was significantly lower than the MCGS recorded in the *M. smegmatis* groups ($p < 0.01$) (Table 1). No granulomas were seen in the kidneys or hearts of this group of fish.

Table 1
Pathogenicity of different strains of mycobacteria in goldfish

| Strain | <i>M. smegmatis</i> mc ² 155 | | <i>M. smegmatis</i> ATCC 19420 | | <i>M. fortuitum</i> ATCC 6841 | | PBS |
|---------------------------------|--|-----------------|-----------------------------------|-----------------|----------------------------------|-----------------|--------|
| CFU/fish | 10 ⁷ | 10 ⁸ | 10 ⁸ | 10 ⁷ | 10 ⁸ | 10 ⁹ | 0.5 ml |
| Number of fish ^a | 19 | 14 | 20 | 32 | 24 | 12 | 45 |
| Mortality ^b (%) | 10.5 | 10 | 40 | 6.3 | 21 | 100 | 4.5 |
| <i>Characteristic pathology</i> | | | | | | | |
| Examined fish ^c | 17 | 12 | 15 | 30 | 16 | 8 | 45 |
| Lesions ^d (%) | 71 | 92 | 86 | 53 | 94 | 100 | 9 |
| MPS ^e | 0.2 | 0.0 | 3.7 | 0.6 | 0.6 | 4.8 | 0.0 |
| MCGS ^f | 4.1 | 7.0 | 2.6 (early) | 1.5 | 3.9 | 0.0 | 0.6 |
| Giant cells | Mild | Mild | Marked | Minimal | Minimal | Normal | Normal |

^aNumber of fish inoculated at the start of the experiment. Numbers represent the total number of fish used in multiple experiments.

^bMortality rate during the 8-week observation period.

^cNumber of fish subjected to histopathological examination. Some fish were found dead and were not used for histological examination.

^dPercentage of overall pathological lesions seen in inoculated animals.

^eMean peritoneal score.

^fMean cumulative granuloma score.

Fish inoculated with 10⁸ cfu of *M. fortuitum* suffered from severe mycobacteriosis with high peritoneal scores, at 2 weeks, followed by a peritoneal chronic granulomatous reaction starting 4 weeks postinfection (Fig. 3(A)). Both necrotizing and caseous granulomatous reactions were seen in *M. fortuitum*-infected fish. Granulomas filled with foamy-appearing macrophages (Fig. 3(B)) were also seen. Peritoneal melanomacrophage centers were occasionally seen in this group of fish while giant cells were rarely present. The GS in the peritoneum was significantly higher ($p < 0.001$) than those recorded in the liver, spleen, kidney and heart. Non-peritoneal, systemic granulomas were seen in only 17% of infected animals.

A severe mycobacteriosis was produced in fish inoculated with 10⁹ cfu of *M. fortuitum* and all fish died within 8 days post-infection with severe peritonitis (peritoneal score, PS = 5). No granulomas were seen in this group of animals (Table 1).

3.3. Histopathology of fish infected with *M. smegmatis*

Fish inoculated with *M. smegmatis* mc²155 showed a severe granulomatous response despite the general belief that it is an avirulent mycobacterial strain (Falcone et al., 1994; Ramakrishnan et al., 1997). At 10⁷ cfu inoculum of *M. smegmatis* mc²155, fish showed moderate peritonitis (PS ranged from 0 to 3) and early granuloma formation when fish examined at 2 weeks post-infection. Fish examined at 4, 6 and 8 weeks postinfection showed histopathological lesions in 85% with more granulomas seen in the peritoneum (62%) compared to the liver, spleen, kidney and heart (31%).

At 10⁸ cfu of *M. smegmatis* mc²155, fish showed a similar pathology (Fig. 4(A)) to those infected with 10⁷ cfu except that greater granuloma scores (Table 1) were seen in

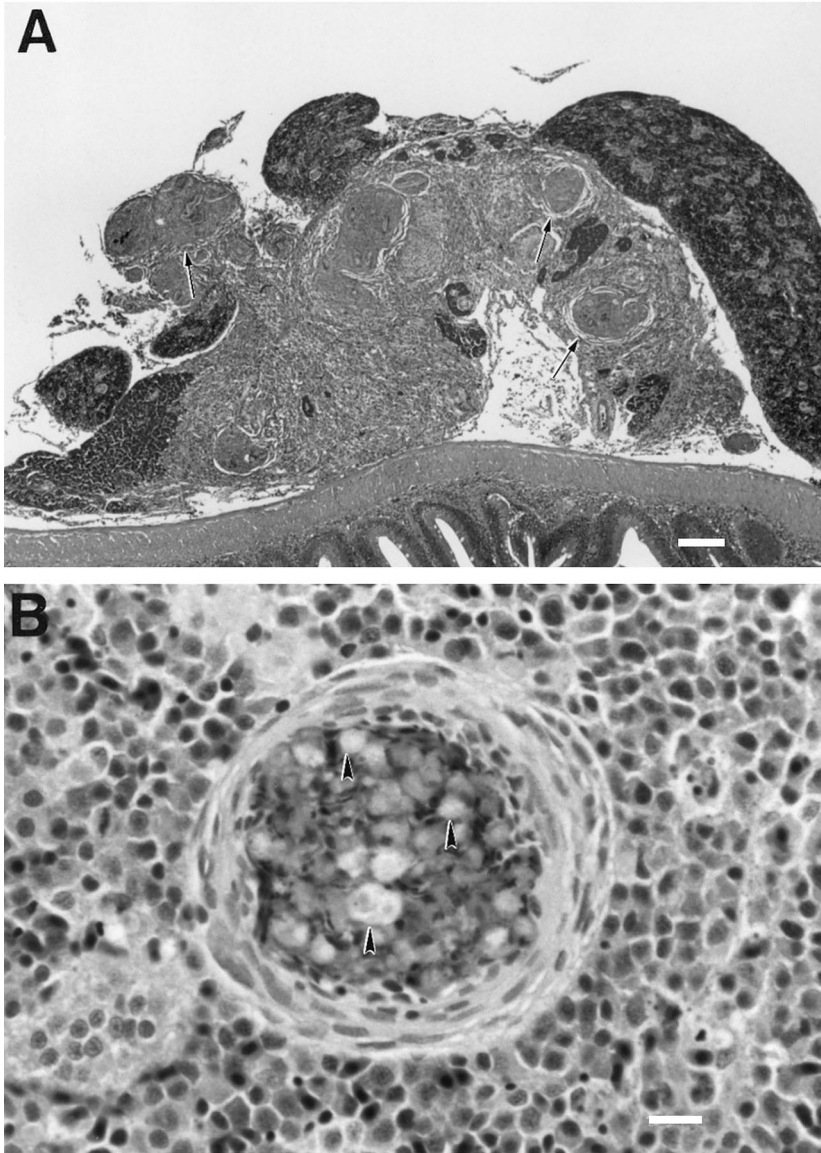


Fig. 3. (A) Chronic inflammatory cells and early granuloma (arrows) formation in the peritoneum of fish inoculated four weeks earlier with *M. fortuitum*, 10^7 cfu. HE stain. Bar = 156 μ m. (B) Granuloma with foamy appearing macrophages (arrowheads) in the kidney of fish inoculated 25 days earlier with *M. fortuitum*, 10^8 cfu. HE stain. Bar = 16 μ m.

all infected fish starting at 2 weeks. From 4 weeks post-inoculation, non-peritoneal (systemic) granulomas were seen in 60% of fish infected with 10^8 cfu compared to 31% in 10^7 cfu group.

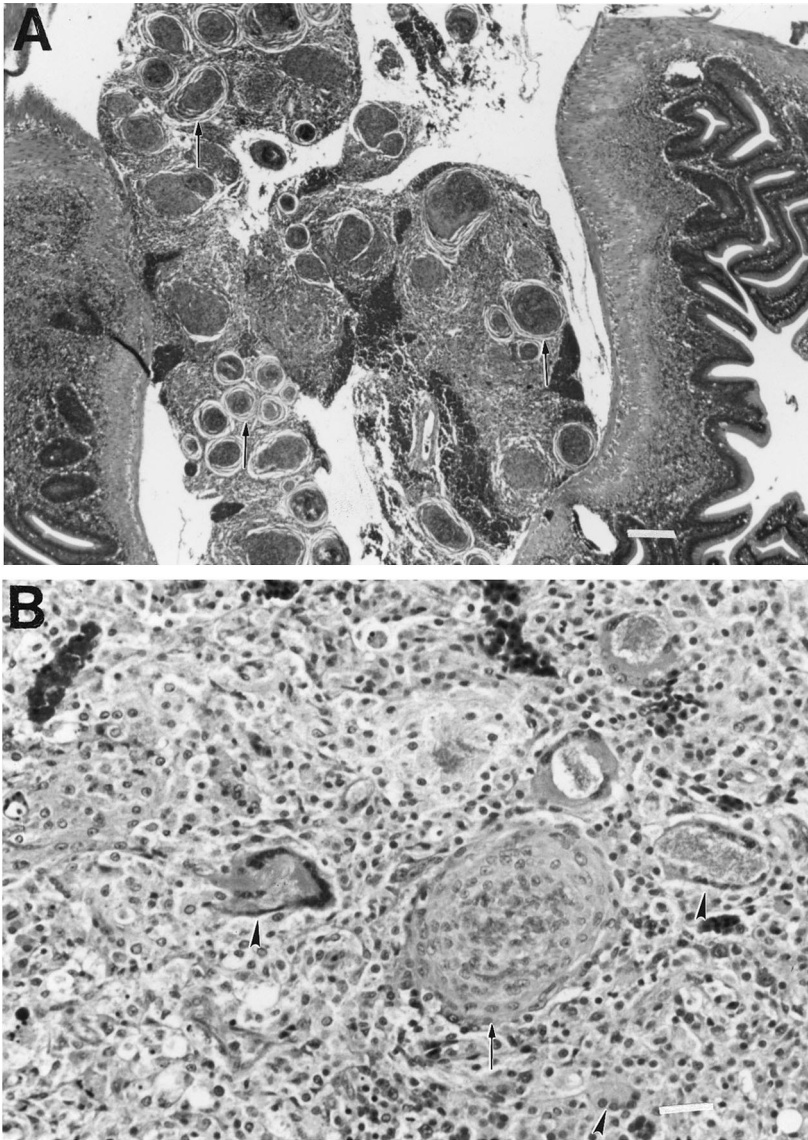


Fig. 4. (A) Granuloma (arrows) formation in the peritoneum of goldfish inoculated 8 weeks earlier with *M. smegmatis* mc²155, 10⁸ cfu. HE stain. Bar = 156 μ m. (B) Giant cells (arrowheads) and early granuloma (arrows) formation in the peritoneum of goldfish inoculated 2 weeks earlier with *M. smegmatis* ATCC 19420, 10⁸ cfu. HE stain. Bar = 63 μ m.

To test the pathogenicity of an alternative strain to *M. smegmatis* mc²155, we inoculated goldfish with *M. smegmatis* ATCC 19420. While the infection with 10⁸ cfu of *M. smegmatis* mc²155 resulted in high granuloma scores, the infection

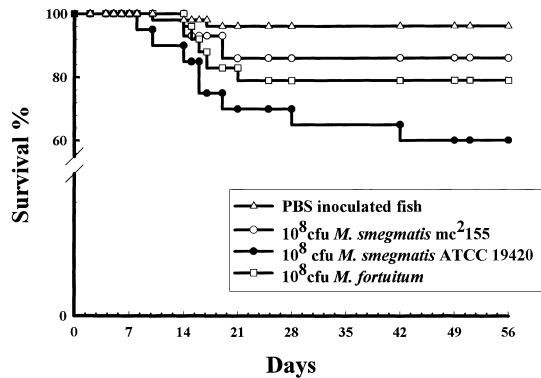


Fig. 5. Survival of fish inoculated with 10^8 cfu of different mycobacteria strains.

with 10^8 cfu *M. smegmatis* ATCC 19420 resulted in marked mean peritoneal inflammation (MPS = 3.7). In addition to the intense inflammatory response, there were numerous giant cells in the peritoneum during early granuloma formation (Fig. 4(B)). Giant cells were not a prominent feature in the *M. smegmatis* mc²155 or *M. fortuitum* infected fish (Table 1).

The majority of control goldfish inoculated with PBS were histopathologically unremarkable. Granulomas were seen in four of 45 fish. Such granulomas in fish are usually caused by previous infection with parasites (e.g. myxozoan sp.), fungi (e.g. *Ichthyophonus*-like spores) or bacteria (e.g. corynebacteria or mycobacteria infection) (Balouet and Baudinlaurencin, 1986). These fish showed no clinical manifestation of mycobacteriosis nor were mycobacteria recovered from their organs.

3.4. Virulence of *M. fortuitum* and *M. smegmatis*

To estimate the virulence of the rapidly growing mycobacteria, goldfish were inoculated with 10^8 cfu of *M. fortuitum* ATCC 6814, *M. smegmatis* mc²155 or *M. smegmatis* ATCC 19420. The survival of inoculated groups was monitored over an 8-week period (Fig. 5). The fish survival rate was mycobacteria species and strain dependent. Animals inoculated with 10^8 cfu of *M. smegmatis* ATCC 19420 had a 40% mortality rate. However, animals inoculated with a similar dose of *M. smegmatis* mc²155 had only a 10% mortality rate (one fish died at 15 days post-inoculation). At 10^7 cfu, *M. smegmatis* mc²155 caused a similar mortality rate to that of the 10^8 cfu group over the 8 week period (Table 1).

To determine the dose effect on the median survival time (MST) of inoculated animals, fish were inoculated with 10^7 , 10^8 and 10^9 cfu of *M. fortuitum*. The MST was dose dependent. All the fish inoculated with 10^9 cfu of *M. fortuitum* died within 8 days postinoculation with an MST of 5 days (Fig. 6) while at 10^8 and 10^7 cfu of *M. fortuitum*, 21% and 6.3% of fish died, respectively. Only two of the 45 PBS-inoculated fish died. No specific pathological lesions were noted in the control animals and the rest of the control fish appeared clinically normal.

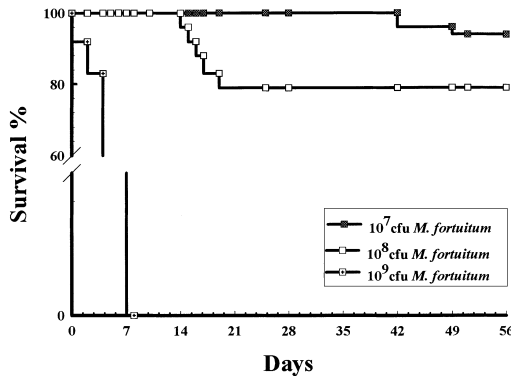


Fig. 6. Survival of fish inoculated with 10^7 , 10^8 and 10^9 cfu of *M. fortuitum*.

4. Discussion and conclusions

In this study, we compared the pathogenicity of two rapidly growing mycobacteria (*M. fortuitum* and *M. smegmatis*) using goldfish. To the best of our knowledge, this is the first report that *M. smegmatis*, considered a non-pathogenic strain of mycobacteria (Shepard, 1957; Falcone et al., 1994; Barker et al., 1996; Ramakrishnan et al., 1997), is pathogenic to fish. We evaluated the virulence of *M. smegmatis* ATCC 19420 as an alternative strain to *M. smegmatis* mc²155, a potential cloning host of mycobacterial genes required for virulence. Using goldfish, we were able to show differences in the virulence of each tested mycobacterial strain. In our model, at an inoculum of 10^8 cfu, *M. smegmatis* ATCC 19420 was the most virulent strain followed by *M. fortuitum* ATCC 6841 and *M. smegmatis* mc²155, respectively.

Surprisingly, our results showed that *M. smegmatis* is pathogenic to fish. Different strains of *M. smegmatis* caused different pathology when inoculated into fish. Fish infected with *M. smegmatis* ATCC 19420 showed a profuse giant cell recruitment in the peritoneum. This host response was not seen in fish infected with *M. smegmatis* mc²155, *M. fortuitum* or *M. marinum*. Moreover, *M. smegmatis* mc²155 elicited a higher level of granuloma formation compared to the well-established fish pathogen, *M. fortuitum* (van Duijn, 1981). Differences in the cell wall of each strain of mycobacteria could be the reason for triggering different cytokines (Fenton and Vermeulen, 1996; Ferguson et al., 1997) with different inflammatory responses. Some cytokines (such as interleukin-4, IL-4 and interferon- γ , IFN- γ) induce giant cell formation from blood monocytes/macrophages (Haynes and Cohen, 1993; Mor and Nicolas, 1994). With the help of either IL-3 or granulocyte-macrophage colony-stimulating factor (GM-CSF), IL-4 induces very large giant cells with up to 285 nuclei, while IFN- γ tends to induce a relatively smaller giant cell (e.g. 16 nuclei per cell) (Kaufman et al., 1990). It is possible that *M. smegmatis* ATCC 19420 strain elicits high levels of IL-4 rather than IFN- γ elicited with other mycobacterial species tested in this study.

In the frog model of mycobacterial infection with an inoculum of 10^8 cfu *M. smegmatis* mc²155, organisms were not detected 28 days postinfection (Ramakrishnan et al., 1997).

In contrast, goldfish infection with a similar inoculum resulted in persistence of mycobacteria in fish organs to the end of the experiment (56 days) with a marked granulomatous reaction.

In comparison to fish infected with the slowly growing, *M. marinum*, fewer caseous granulomas were seen in fish infected with *M. smegmatis* and *M. fortuitum*. By 8 weeks postinoculation, systemic granulomas (kidney and heart granulomas) were detected in 20% of *M. smegmatis*-inoculated fish compared to 88% in the *M. marinum* group (Talaat et al., 1998). On the other hand, *M. fortuitum* inoculated fish showed no systemic granulomas during the same time period using a similar inoculum (10^7 cfu/fish).

Fish infected with *M. fortuitum* showed no sign of nervous system involvement, but histopathological lesions were found in the peritoneum, pancreas, liver, spleen, heart in addition to the kidney, especially with the 10^8 cfu inoculum. In the mouse model, *M. fortuitum* induced kidney and nervous system (brain and inner ear) lesions (Saito and Tasaka, 1969). In both the animals (mice and fish) granulomas were seen in the examined organs.

Using goldfish, we have shown varying pathological responses among fish groups infected with different species and strains of mycobacteria. These differences suggest differences in the virulence of each mycobacterial strains. This model system of mycobacterial infection will be useful for further studies into the pathogenesis of atypical mycobacteria. It is an excellent model for dissecting the genetic basis of the virulence of the rapidly growing mycobacteria.

Acknowledgements

This work was supported in part by the Office of Research and Development, Medical Research Service, Department of Veteran Affairs and University of Maryland School of Medicine (M.T.). We thank Tim Conn and Richard Milanich for expert technical assistance.

References

- Alvarez, T., 1885. Recherches sur les bacille de Lustgarten. *Arch Physiol. Normal Pathol.* 2, 203–221.
- Balouet, G., Baudinlaurencin, F., 1986. Granulomatous nodules in fish: An experimental assessment in rainbow trout, *Salmo gairdneri* Richardson, and turbot, *Scophthalmus maximus* (L.). *J. Fish Dis.* 9, 417–429.
- Barker, K., Fan, H.X., Carroll, C., Kaplan, G., Barker, J., Hellmann, W., Cohn, Z.A., 1996. Nonadherent cultures of human monocytes kill *Mycobacterium smegmatis*, but adherent cultures do not. *Infect. Immun.* 64, 428–433.
- Belas, R., Faloon, P., Hannaford, A., 1995. Potential applications of molecular biology to the study of fish mycobacteriosis. *Ann. Rev. Fish Dis.* 5, 133–173.
- Bloom, J.M., 1885. The bacillus of syphilis. *Lancet.* 1, 609–610.
- Brown, T.H., 1985. The rapidly growing mycobacteria – *Mycobacterium fortuitum* and *Mycobacterium chelonae*. *Infect. Contr.* 6, 283–288.
- Cruz, J.C., 1938. *Mycobacterium fortuitum*, um novo bacilo acido-resistente patogenico para o Homem. *Acta Med. Rio de Jan.* 1, 297–301.

- Daoust, P.Y., Larson, B.E., Johnson, G.R., 1989. Mycobacteriosis in Yellow Perch (*Perca flavescens*) from two lakes in Alberta. *J. Wildl. Dis.* 25, 31–37.
- Ellis, R.C., Zabrowarny, L.A., 1993. Safer staining method for acid fast bacilli. *J. Clin. Pathol.* 46, 559–560.
- Falcone, V., Basse, E.B., Toniolo, A., Conaldi, P.G., Collins, F.M., 1994. Differential release of tumor necrosis factor-alpha from murine peritoneal macrophages stimulated with virulent and avirulent species of mycobacteria. *FEMS Immunol. Med. Microbiol.* 8, 225–232.
- Fenton, M.J., Vermeulen, M.W., 1996. Immunopathology of tuberculosis: Roles of macrophages and monocytes. *Infect. Immun.* 64, 683–690.
- Ferguson, J.S., Gaynor, C.D., Schlesinger, L.S., 1997. Mononuclear phagocytes in tuberculosis pathogenesis. *Curr. Opin. Infect. Dis.* 10, 190–195.
- Fox, L.E., Kunkle, G.A., Homer, B.L., Manella, C., Thompson, J.P., 1995. Disseminated subcutaneous *Mycobacterium fortuitum* infection in a dog. *J. Am. Vet. Med. Assoc.* 206, 53–55.
- Goslee, S., Wolinsky, E., 1976. Water as a source of potentially pathogenic mycobacteria. *Am. Rev. Resp. Dis.* 113, 287–292.
- Grooters, A.M., Couto, C.G., Andrews, J.M., Johnson, S.E., Kowalski, J.J., Esplin, R.B., 1995. Systemic *Mycobacterium smegmatis* infection in a dog. *J. Am. Vet. Med. Assoc.* 206, 200–202.
- Haynes, L., Cohen, N., 1993. Transforming growth factor beta (TGF beta) is produced by and influences the proliferative response of *Xenopus laevis* lymphocytes. *Develop. Immunol.* 3, 223–230.
- Hedrick, R.P., McDowell, T., Groff, J., 1987. Mycobacteriosis in cultured striped bass from California. *J. Wildl. Dis.* 22, 391–395.
- Jacobs Jr., W.R., Kalpana, G.V., Cirillo, J.D., Pascopella, L., Snapper, S.B., Udani, R.A., Jones, W., Barletta, R.G., Bloom, B.R., 1991. Genetic systems for mycobacteria. *Methods. Enzymol.* 204, 537–555.
- Jang, S.S., Eckhaus, M.A., Saunders, G., 1984. Pulmonary *Mycobacterium fortuitum* infection in a dog. *J. Am. Vet. Med. Assoc.* 184, 96–98.
- Kamala, T., Paramasivan, C.N., Herbert, D., Venkatesan, P., Prabhakar, R., 1994. Isolation and Identification of environmental mycobacteria in the *Mycobacterium bovis* BCG trial area of south India. *Appl. Environ. Microbiol.* 60, 2180–2183.
- Kaufman, J., Skjoedt, K., Salomonsen, J., 1990. The MHC molecules of nonmammalian vertebrates. *Immunol. Rev.* 113, 83–117.
- Mor, A., Nicolas, P., 1994. Isolation and structure of novel defensive peptides from frog skin. *Eur. J. Biochem.* 219, 145–154.
- Newton Jr., J.A., Weiss, P.J., Bowler, W.A., Oldfield 3d, E.C., 1993. Soft-tissue infection due to *Mycobacterium smegmatis*: Report of two cases. *Clin. Infect. Dis.* 16, 531–533.
- Newton Jr., J.A., Weiss, P.J., 1994. Aspiration pneumonia caused by *Mycobacterium smegmatis*. *Mayo Clinic Proc.* 69, 296.
- Parish, T., Stoker, N.G., 1995. Electroporation of mycobacteria. *Methods. Molec. Biol.* 47, 237–252.
- Prophet, E.B., 1992. Tissue processing: dehydration, clearing, and infiltration. In: Prophet, E.B., Mills, B., Arrington, J.B., Sobin, L.H. (Eds.), *Laboratory Methods in Histotechnology*. American Registry of Pathology, Washington, DC, pp. 29–32.
- Ramakrishnan, L., Valdivia, R.H., McKerrow, J.H., Falkow, S., 1997. *Mycobacterium marinum* causes both long-term subclinical infection and acute disease in the leopard frog (*Rana pipiens*). *Infect. Immun.* 65, 767–773.
- Reimschuessel, R., Bennett, R.O., Lipsky, M.M., 1992. A classification system for histological lesions. *J. Aquat. Anim. Health.* 4, 135–143.
- Richardson, A., 1971. The experimental production of mastitis in sheep by *Mycobacterium smegmatis* and *Mycobacterium fortuitum*. *Cornell. Veterinarian.* 61, 640–646.
- Runyon, E.H., 1959. Anonymous mycobacteria in pulmonary disease. *Med. Clin. North. Am.* 43, 273–290.
- Saito, H., Tasaka, H., 1969. Comparison of the pathogenicity for mice of *Mycobacterium fortuitum* and *Mycobacterium abscessus*. *J. Bacteriol.* 99, 851–855.
- Shepard, C.C., 1957. Growth characteristics of tubercle bacilli and certain other mycobacteria in HeLa cells. *J. Exp. Med.* 105, 39–55.
- Snapper, S.B., Melton, R.E., Mustafa, S., Kieser, T., Jacobs Jr., W.R., 1990. Isolation and characterization of efficient plasmid transformation mutants of *Mycobacterium smegmatis*. *Mol. Microbiol.* 4, 1911–1919.

- Talaat, A., Reimschuessel, R., Trucksis, M., 1998. Goldfish, *Carassius auratus*, a novel animal model for the study of *Mycobacterium marinum* pathogenesis. *Infect. Immun.* 66, 2938–2942.
- Talaat, A.M., Reimschuessel, R., Trucksis, M., 1997. Identification of mycobacteria infecting fish to the species level using polymerase chain reaction and restriction enzyme analysis. *Vet. Microbiol.* 58, 229–237.
- Thomson, J.R., Mollison, N., Matthews, K.P., 1988. An investigation of mastitis due to *S. agalactiae*, *S. uberis* and *M. smegmatis* in a dairy herd. *Vet. Rec.* 122, 271–274.
- van Duijn, C., 1981. Tuberculosis in fish. *J. Sm. An. Pract.* 22, 391–411.
- Wallace, R.G.J., Silcox, V., Brown, B.A., 1994. Taxonomy of rapidly growing mycobacteria. *Clin. Infect. Dis.* 18, 121–122.
- Wallace Jr., R.J., Nash, D.R., Tsukamura, M., Blacklock, Z.M., Silcox, V.A., 1988. Human disease due to *Mycobacterium smegmatis*. *J. Infect. Dis.* 158, 52–59.
- Wilkinson, G.T., Kelly, W.R., O'Boyle, D., 1978. Cutaneous granulomas associated with *Mycobacterium fortuitum* in a cat. *J. Sm. An. Pract.* 19, 357–362.
- Woods, G.L., Washington II, J.A., 1987. Mycobacteria other than *Mycobacterium tuberculosis*: review of microbiological and clinical aspects. *Rev. Infect. Dis.* 9, 275–294.
- Yew, W.-W., Wong, P.-c., Woo, H.-s., Yip, C.-w., Chan, C.-y., Cheng, F.-b., 1993. Characterization of *Mycobacterium fortuitum* isolates from sternotomy wounds by antimicrobial susceptibilities, plasmid profiles, and ribosomal ribonucleic acid gene restriction patterns. *Diagn. Microbiol. Infect. Dis.* 17, 111–117.